

---

## THERAPEUTIC MANAGEMENT OF GENERALIZED CANINE DEMODICOSIS WITH SECONDARY BACTERIAL AND YEAST INFECTIONS-A CASE REPORT

Fidha Sherin V.<sup>1</sup>, Shamnu Sherin<sup>2</sup>, Sneha Sasi<sup>3</sup> and Deepa. P.M<sup>4\*</sup>

Associate Professor<sup>4</sup>, Final Year BVSc & AH scholars<sup>123</sup>

Department of Preventive Veterinary Medicine,  
College of Veterinary and Animal Sciences, Pookode

\*Corresponding Author: [deepapm@kvasu.ac.in](mailto:deepapm@kvasu.ac.in)

---

### ABSTRACT

Anine-month-old female Doberman Pinscher dog weighing 25 kg was presented with the complaint of generalized skin lesions and pruritus. On clinical examination alopecia, scale and crust formation and hyperkeratosis were noticed. Laboratory diagnosis revealed demodicosis with pyoderma and malasseziosis. The *Demodex canis* was detected in deep skin scraping and budding yeast on impression smear. Culture of skin swab revealed the presence of *Pseudomonas aeruginosa*. Therapeutic management with fluralaner, enrofloxacin, Benzyl peroxide shampoo, piroctone olamine shampoo, immune boosters and omega 3 and omega 6 fatty acids was carried out. Animal showed uneventful recovery one month after treatment.

**Keywords:** dog, demodicosis, pseudomonas, pyoderma

### INTRODUCTION

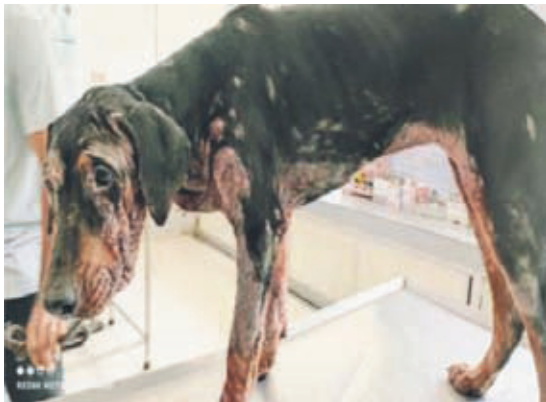Canine demodicosis, also called demodectic mange or follicular mange or red mange, is a common skin disease encountered in veterinary practice. It is an inflammatory parasitic disease caused by demodectic mites *Demodex canis* or *Demodex injai*. The entire life cycle is completed on skin especially within hair follicle and rarely in sebaceous glands by feeding cells, sebum, epidermal debris etc. It results in folliculitis, furunculosis, hyperpigmentation, hyperkeratosis and alopecia and clinically presented as localised/generalised or juvenile/adult onset (Mueller,2012).

Skin infection due to *Demodex canis* can predispose to secondary infections like Malassezia dermatitis caused by *Malassezia pachydermatis* and bacterial pyoderma. It may have a symbiotic relationship with *Pseudomonas* spp. which

causes pyoderma. Concurrent pyoderma can complicate dermatitis which may prolong the treatment (Umesh et al., 2016). This paper describes about generalized demodicosis with secondary bacterial and yeast infections and its successful therapeutic management.


**CASE HISTORY AND OBSERVATION**

A nine month old female Doberman Pinscher dog with a body weight of 25 kg was presented with a complaint of generalized itching and patchy alopecia since last two weeks. The animal was previously treated without any clinical improvement with oflaxcin and clotrimazole ear drops and cephalexin@25 mg/kg body weight for periocular lesions. On clinical examination, alopecia with folliculitis, erythematous, crusty, scaly exudative lesions were noticed on the face, around eyes, ears, neck, ventral abdomen and limbs along with unpleasant odour. Hyperpigmentation on ventral aspect of abdomen was noticed. (Fig1)

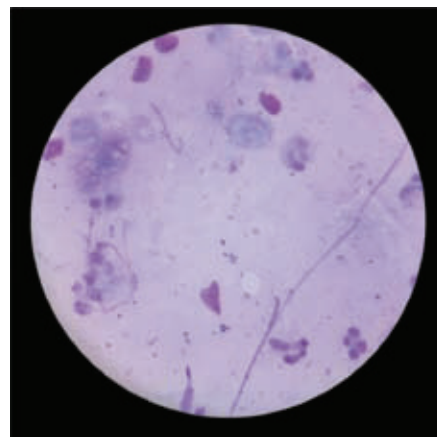


**Fig 1.** Before treatment

Microscopic examination of deep skin scrapings revealed the presence of extruded cigar shaped organism with four pairs of clawed legs suggestive of adult *Demodex canis* (Fig2). Field staining of impression smear revealed the presence of cocci and budding yeast (Fig3). *Pseudomonus aeruginosa* was isolated from the skin swab while culturing on brain heart infusion agar and was identified by using Gram’s staining, catalase test, oxidase test and biochemical tests (Fig. 4,5,6,7). Antibiotic sensitivity test revealed sensitivity to enrofloxacin and neomycin and resistance to tetracycline, amoxiclav, cotrimazole, cefpodoxime and cephalixin. (Fig.8).



**Fig:2.** *Demodex canis* (40X and 10X)



**Fig:3** *Malassezia spp* and cocci (10X)

## TREATMENT AND DISCUSSIONS

The animal was given the following medications to manage the condition; Fluralaner 25mg per kg body weight OD orally once, Enrofloxacin @ 5 mg per kg BID orally for 7 days, Itraconazole @10mg/kg orally OD for 21 days and Pantoprazole @1 mg per kg OD orally. For external application, Benzyl peroxide shampoo and Piroctone olamine shampoo alternatively once in week for one month were prescribed. Supportive treatment with Omega 3 and omega 6 fatty acids for reducing inflammation and immunity boosters was advised during the period of treatment. Animal showed uneventful recovery after one month of treatment (Fig 8).

Canine demodicosis is one of the frequently encountered dermatopathy of canines as a result of the excessive proliferation of acarian parasite, *Demodex canis* associated with the development of cutaneous skin lesions and immunosuppression (Sivajothi *et al.*, 2015). The dogs suffering from generalized demodicosis revealed a wide variety of clinical manifestations. The signs associated with the conditions are attributable to irritation and inflammatory reaction caused by mites in the hair follicles resulting in damage of the epidermal cells and exudation produced by

secondary bacterial and fungal infection (Mueller *et al.*, 1989). The majority of the bacterial skin infections of dogs is caused by *Staphylococcus pseudintermedius* and if there is immunosuppression or the infection goes deeper other organisms like small rods causes concurrent pyoderma. Generalized demodicosis is mostly associated with secondary bacterial pyoderma and thus requiring prolonged treatment (Mueller, 2012). Therapeutic options that are currently available include amitraz, ivermectin, milbemycin oxime and moxidectin, mostly to be given at multiple occasions for periods of three months or more (Mueller, 2004; Paterson *et al.*, 2014). Amitraz is the drug approved for canine generalized demodicosis. However, it is not always effective or well tolerated by the patient (Paradis, 1999). Use of macrocyclic lactones also has certain limitations because their prolonged use may be associated with adverse effects (Mueller, 2012).

Fluralaner, is a novel, long-acting systemic insecticide and acaricide belonging to the isoxazoline class of parasiticides with selective inhibition of arthropod  $\gamma$ -aminobutyric acid- and L-glutamate-gated chloride channels (Gassel *et al.*, 2014). A single oral administration of Bravecto™ chewable tablets to dogs with naturally acquired generalized demodicosis resulted in significantly lower mean mite counts 56 and 84 days after treatment (Fourie *et*

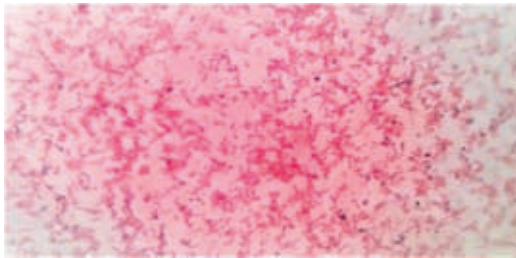


Fig 4. Gram-negative rod-shaped bacteria(100X)



Fig.5 Catalase positive

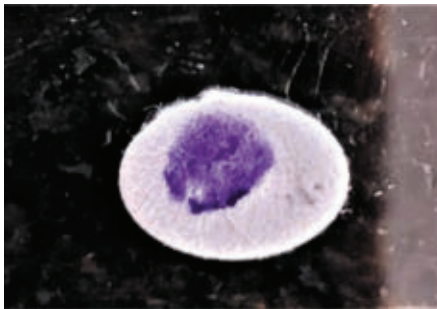


Fig 6. Oxidase positive

al., 2015). Our study shows the efficacy of fluralaner in treatment of generalized demodicosis in dogs.

## CONCLUSION

Demodicosis is a common mite infestation in young dogs with localized and generalized (juvenile- and adult-onset) forms and cause suppression of cell mediated immunity that can predispose to bacterial and fungal infections. This case

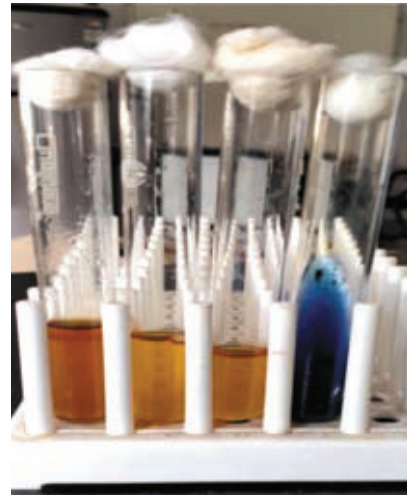

Fig 7. Battery of biochemical tests for Pseudomonas

1. Indole: Negative
2. Methyl red : Negative
3. Voges-proskauer: Negative
4. Citrate utilisation: Positive

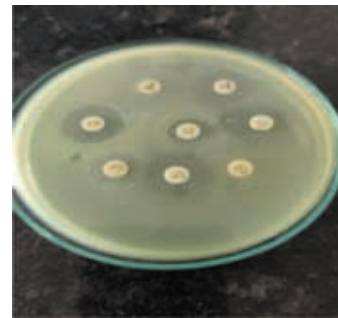


Fig 8. Antibiotic sensitivity test



Figure 8. Doberman Pinscher dog after treatment

study reports generalized demodicosis in nine-year-old dog with concurrent malasseziosis and pyoderma caused by *Pseudomonas aeruginosa*. The study also reports the efficacy of fluralaner in the treatment of generalized demodicosis along with antibiotics based on culture and sensitivity test and antifungal medication.

## REFERENCES

- Fourie, J.J., Liebenberg, J.E., Horak, I.G., Taenzler, J., Heckerroth, A.R. and Frenais, R. 2015. Efficacy of orally administered fluralaner (Bravecto™) or topically applied imidacloprid/moxidectin (Advocate®) against generalized demodicosis in dogs. *Parasites Vectors* .8:187.
- Gassel, M., Wolf, C., Noack, S., Williams, H. and Ilg, T. 2014. The novel isoxazolineectoparasiticide fluralaner: Selective inhibition of arthropod  $\gamma$ -aminobutyric acid- and L-glutamate-gated chloride channels and insecticidal/acaricidal activity. *Insect Biochem. Mol. Biol.* **45**:111–24.
- Mueller, R.S. 2004. Treatment protocols for demodicosis: an evidence-based review. *Vet. Dermatol.* **15**:75–89.
- Mueller, G. H., Krik, R. W. and Scott, D. W. 1989. *Small Animal Dermatology* 3rd Ed. W.B Saunders Company. Philadelphia. pp 76-95.
- Mueller, R.S. 2012. An update on the therapy of canine demodicosis. *Compend. Contin. Educ. Vet.* **34**: E1-4.
- Paradis M. 1999. New approaches to the treatment of canine demodicosis. *Vet. Clin. North Am. Small Anim. Pract.* **29**:1425-36.
- Paterson, T.E., Halliwell, R.E., Fields, P.J., Louw, M.L., Ball, G., Louw, J. and Pinckney, R. 2014. Canine generalized demodicosis treated with varying doses of a 2.5% moxidectin+10% imidacloprid spot-on and oral ivermectin: Parasitocidal effects and long-term treatment outcomes. *Vet. Parasitol.* **205**:687–96.
- Sivajothi, S., Sudhakar Reddy, B. and Rayulu, V.C. 2015. Demodicosis caused by *Demodex canis* and *Demodex cornei* in dogs. *J. Parasit. Dis.* **39**: 673-6.
- Umesh. C.G., Manju, K.M., Sindhu, O.K., Arun George, and Usha Narayanapillai. 2016. Successful medical management of concurrent canine demodicosis, malasseziosis and associated pyoderma in a pug. *J. Indian Vet. Assoc.* **14**:37-40.