
UTERINE ANASTOMOSIS IN A BEAGLE DOG- A CASE REPORT

Anoop R ^{1*}, Ananthapadmanabhan T. P ², Ajin S. Kumar ³ and Rekha A ⁴.

¹Veterinary Surgeon, Multi Speciality Veterinary Hospital,
Kudappanakunnu, Trivandrum, Kerala- 695043,

²M.V.Sc. Scholar, Dept. of Animal Reproduction, Gynaecology and Obstetrics ,
College of Veterinary and Animal Sciences, Mannuthy, Thrissur – 680651,

³M.V.Sc. Scholar, Dept. of Veterinary Surgery and Radiology,

College of Veterinary and Animal Sciences, Mannuthy, Thrissur - 680651

⁴Food Safety Officer, Chathannoor circle, Mini Civil Station, Kollam, Kerala-691572

*Corresponding author Email: anoopvet@gmail.com

ABSTRACT

A two year old female beagle dog was presented to Multispeciality Veterinary Hospital, Kudappanakunnu, Thiruvananthapuram with whelping signs. The owner reported that the animal was mated 62 days ago and was showing whelping signs since the past night along with a whitish fluid discharge from vulva. All physiological parameters were within normal range. On Radiographic Examination eight fetal skeletons was observed. On ultrasonographic examination, live fetuses with low fetal heart rate were observed hence Caesarean Section was advised as the treatment option. On laparotomy under general anaesthesia, to our surprise it was observed that one of the uterine horns was transversely ruptured and was a fresh defect. Eight puppies in total which were recovered, out of which 2 were live and 6 were dead. Uterine anastomosis was adopted as the surgical correction

considering the patient's health and its future reproductive life. With antibiotics and analgesics as post-surgical medication and with good care and management the patient had an uneventful recovery.

Keywords: Dog, Caesarean section, uterine rupture, uterine anastomosis

INTRODUCTION

Caesarean section in dogs is very common and useful in the clinical management of dystocia in veterinary practice. If medical therapy as primary attempt fails, C-Section is the trump card. The small size of canines, multiparous nature, a long duration of delivery and the demands by the owner to deliver as many live puppies as possible due to commercial considerations possibly forces the veterinary obstetrician/surgeon to increasingly employ caesarean section in bitches. The rupture of the uterus in bitches is an acute, life-threatening condition

usually observed by the end of pregnancy or during parturition that appears most commonly as a result of dystocia and is one of the rarely diagnosed clinical entities in canine. The present case was diagnosed as dystocia and advised caesarean section based on history, clinical signs, physical examination, ultrasonography and radiography. But to our surprise when performed, this laparotomy turned out to be a case of uterine rupture and its surgical correction by uterine anastomosis

CASE HISTORY AND OBSERVATION

A two year old female beagle dog was presented to Multispecialty Veterinary Hospital, Kudappanakkunnu, Thiruvananthapuram with a history of the animal showing whelping signs since the previous night along with a white fluidy vulval discharge. The animal presented was reportedly showing whelping signs since the past night along with a whitish fluid discharge from vulva. The animal was anorectic and has been vomiting since the past two days. The owner reported that the animal was mated 62 days ago. On Radiographic Examination around eight fetal skeletons could be observed. On Ultrasonographic examination, fetal heart rate of 170 bpm could be observed indicative of a live fetus and on measurement of the head diameter of the fetus, the expected delivery date was two

days after the date of presentation of the animal to the hospital. However, a low fetal heart rate was an indicative of reduced

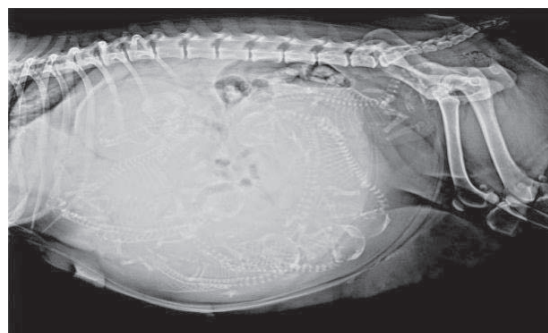

Figure 1. Fetal skeletons observed on radiography

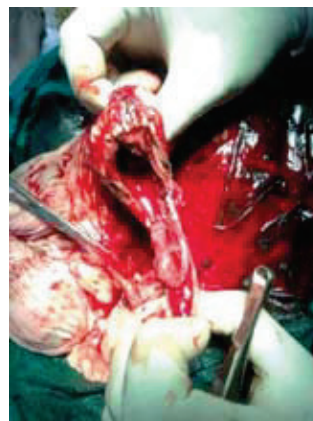

Figure 2. Uterine rupture detected on laparotomy

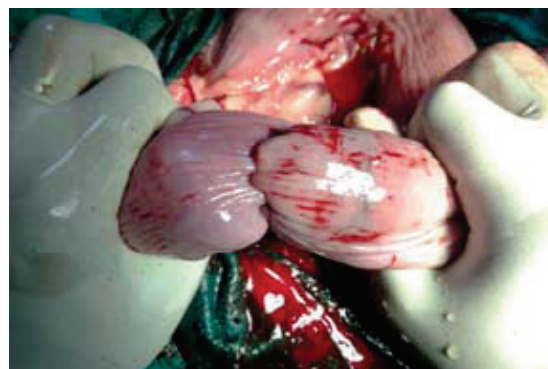


Figure 3. Surgical correction by uterine anastomosis

fetal viability and hence Caesarean Section was advised as the treatment option. But as we proceeded with the surgery it was



Figure 4. After wound dressing

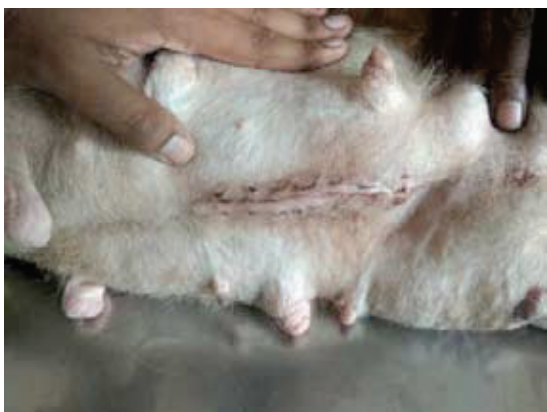

Figure 5. Six dead and two live puppies

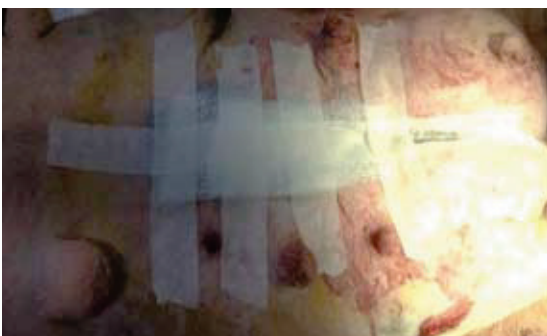

Figure 6. After 14 days

observed that one of the uterine horns was transversely ruptured and it looked to be a fresh defect. There were eight puppies in total which were recovered, out of which 2 were live and 6 were dead. Uterine anastomosis was adopted as the surgical correction considering the patient's health and its future reproductive life.

TREATMENT AND DISCUSSIONS

The surgical procedure was performed immediately. Food and water were withheld from the day for a period of 12 hours preoperatively as the animal was anorectic for past two days. Ceftriaxone Tazobactam was injected at the rate of 25mg/kg body weight intravenously as prophylactic antibiotic half an hour before the surgery. The dog was premedicated with Atropine (0.045mg/kg) and Dexamethasone (0.5mg/kg), subcutaneously; Anaesthesia was induced with Ketamine and Diazepam at a dose rate of Ketamine at 5 mg/kg body weight and Diazepam 0.5mg/kg body weight. Maintenance was done using Ketamine and Midazolam taken in the ratio 4:1. The animal was placed on dorsal recumbency; surgical site was draped with sterile drape, exposing the ventral abdominal region. An intravenous infusion of isotonic normal saline (0.9%) was administered throughout the period of surgery at the rate of 10ml/kg/hour. A ventral midline incision was made beginning 2-3 cm caudal to the xiphoid and extending to the pubis. Incised the skin, subcutis and fascia. Separated the subcutis. An incision was made on the Linea Alba. On reaching the peritoneum, the uterus was found to be ruptured and the puppies were found in the uterine horn as well as the peritoneum. On examination

of the uterus, it was found that there were transverse ruptures at two places on the left uterine horn. On further examination, it was clear that the rupture was very fresh (may have happened two or three hours before). Considering the animal's health status and future reproductive life, uterine anastomosis was adopted as the surgical option. The normal incision for surgical Caesarean section was not placed and all the puppies were removed through the already ruptured uterine sites. Puppies were one by one removed out of the peritoneal cavity and from the uterine body. There were eight puppies in total out of which 2 were live and 6 were dead (one puppy was severely malformed and was immediately discarded). Uterine anastomosis was done using Polyglycolic acid (3-0) {RC}. Peritoneum was washed thoroughly with diluted Metronidazole solution and the fluid was removed using suction. Muscle and subcutis was closed in the simple continuous suture pattern using polyglycolic acid (2-0) {RC}. The skin was then apposed in a horizontal mattress suture pattern using Nylon (3-0) suture. The site was then dressed properly after the application of antibiotic spray. Post-operative antibiotic therapy was instituted using Ceftriaxone tazobactam at the dose rate of 25mg/Kg body weight for 7 days; Analgesic – Meloxicam at the dose rate of 0.2 mg/Kg for 3 days. The suture line

was dressed with Metronidazole-Povidone iodine ointment routinely. Skin sutures were removed on the 14th Post-operative day. Since uterine anastomosis was adopted considering the patient's health and its future reproductive life, the animal had an uneventful recovery and the uterus was healed completely, reducing the risks for any future complications related to conception.

CONCLUSION

A case of uterine rupture, its diagnosis, correction and management by uterine anastomosis is documented. Uterine ruptures in canines even though rare, are encountered during Caesarean sections and in such situations it is recommended that we adopt uterine anastomosis as the surgical correction method without any hesitation considering the health of the patient, severity of the uterine damage and future reproductive life of the animal. Keeping in mind these points and performing uterine anastomosis, we can successfully treat uterine rupture cases in canines.

ACKNOWLEDGEMENT

We would like to express our gratitude to Department of Animal Husbandry, Kerala State, Veterinarians and all the supporting staff of MSVH, Kudappanakunnu. . We dedicate this work to Almighty the supreme and also to my

parents without whose blessings and love this work would not have been possible. We thank the owner of our patient for their complete faith in us and their whole hearted support during the treatment.

REFERENCES

- Davidson, A.P. 2014. Neonatal resuscitation- Improving the outcome. *Vet. Med. Small Anim. Clin.* 44:191-204
- Fossum. T. (2019) Surgery of the reproductive tract and the genital systems. *Small animal surgery. 5th Edition*, Mosby Elsevier, Philadelphia. pp : 735-738
- Johnston, S.D., Kustritz, M.V.R. and Olson, P.N.S. 2001. *Canine and feline theriogenology*. Philadelphia, W. B. Saunders, p. 117.
- Linde-Forsberg, C. 2005. Abnormalities in pregnancy, parturition, and the periparturient period. *Textbook of Veterinary Internal Medicine*. Philadelphia: W.B. Saunders. pp: 1655-1667.
- Moon, P. F., Erb, H. N., Ludders J. W., Gleed, R. D., Pascoe, P. J. 1998. Perioperative management and mortality rates of dogs undergoing caesarean section in the United States and Canada. *J. Am. Vet. Med. Assoc.* 213: 365-369
- Narasimhamurthy., Devaraj, M., Krishnaswamy, A., Honnappa, T. G. 2014. Relative Efficacy Of Various Treatment Procedures Employed To Relieve Dystocia In Canines Department of Veterinary Gynaecology and Obstetrics Veterinary College, Hebbel, Bangalore. *IJAR.* 35.
- Slatter, D., (2003). *Textbook of small animal surgery. 3rd Edition*. Elsevier Science, USA. pp: 1487
- Stone, E., Cantrell, C. and Charp, N. 1993. Reproductive system. *The Textbook of Small Animal Surgery*, 2ndedn. W.B. Saunders, Philadelphia. pp. 1293–1308.
- Thornton, S., Gillespie, J.I., Greenwell, J.R. and Dunlop, W. 1992. Mobilization of calcium by the brief application of oxytocin and prostaglandin E₂ in single cultured human myometrial cells. *Exp. Physiol.* 77: 293-305.